

Multicentric reticulohistiocytosis revealing a ductal breast cancer in situ: A case report with dermoscopic and histopathological findings

Sofía Palma Peña^a, Gabriel Neely Erdos^{b*}, Catalina Buchroithner Haase^b, Claudio Pinto Viguera^c

^aUniversidad Mayor, Santiago, Chile; ^bUnidad de Dermatología, Centro de Referencia de Salud Hospital Provincia Cordillera, Santiago, Chile; ^cComplejo Asistencial Dr. Sótero del Río, Puente Alto, Chile

ABSTRACT

Multicentric reticulohistiocytosis is a rare non-Langerhans cell histiocytosis of unknown etiology. It is classified as multicentric because of multisystem involvement. The disease predominantly affects the skin and joints, but visceral involvement is possible. Multiple erythematous-brownish, pruritic nodules and papules on the face, hands, neck, and trunk are characteristic. It is associated with autoimmune diseases, or malignant neoplasms which are seen in 20% to 30% of patients with multicentric reticulohistiocytosis. The diagnosis is based on histopathology of affected tissues. As it is an underreported disease, there is no standardized treatment. We report a case of multicentric reticulohistiocytosis as a paraneoplastic manifestation of ductal breast cancer, being successfully treated with no recurrence after two years of follow-up. Few cases of multicentric reticulohistiocytosis associated with breast cancer have been reported in the literature.

KEYWORDS Multicentric reticulohistiocytosis, histiocytic disorder, dermatoscopy, breast cancer

INTRODUCTION

Multicentric reticulohistiocytosis is a rare non-Langerhans cell histiocytosis of unknown etiology [1–6]. Only approximately 300 cases have been described in the literature [4]. The disease predominantly affects the skin and joints, but visceral involvement is possible [3–7]. It mainly involves women in the fifth and sixth decade of life with a female-to-male ratio 3:1 [4–6].

Cutaneous manifestations are characterized by multiple erythematous-brownish, pruritic nodules and papules on the face, hands, neck, and trunk [1,8,9]. Periungual "coral bead necklace" papules are present in half of the patients and represent a typical sign of multicentric reticulohistiocytosis [1,10]. The clinical presentation can sometimes be confused with dermatomyositis or rheumatoid arthritis [1,4].

Common symptoms of multicentric reticulohistiocytosis include fever, poor general condition, asthenia, and weight loss [1]. Systemic involvement includes pleural and pericardial effusion, congestive heart failure, and mesenteric lymphadenopathy [4]. It is associated with hyperlipidemia, positive tuberculin test, systemic vasculitis, autoimmune diseases, and malignancies. The association with malignant neoplasms has been observed in 20-30% of patients with multicentric reticulohistiocytosis [1–10].

The diagnosis of multicentric reticulohistiocytosis is based on histopathology of affected tissues [1,4,5,9], showing a typical infiltrate composed of histiocytes and multinucleated giant cells with eosinophilic cytoplasm and ground-glass appearance [1–10]. Dermoscopy can be helpful for diagnosis, with the detection of yellow/orange spots highly indicative of a histiocytic infiltrate in the dermis [8].

Radiological investigations should be performed in all patients with multicentric reticulohistiocytosis to detect possible neoplasms according to sex and age at presentation [6,9]. 18F-fluorodeoxyglucose positron emission tomography/computed tomography (FDG-PET/CT) has high overall sensitivity and specificity for detecting cancer. However, its access is challenged by its costs [1,7].

Although there is no standardized treatment for multicentric reticulohistiocytosis, non-steroidal anti-inflammatory drugs,

* Corresponding author gneelye@gmail.com

Citation Palma Peña S, Neely Erdos G, Buchroithner Haase C, Pinto Viguera C. Multicentric reticulohistiocytosis revealing a ductal breast cancer in situ: A case report with dermoscopic and histopathological findings. Medwave 2024;24(5):e2917

DOI 10.5867/medwave.2024.05.2914

Submitted Jan 31, 2024, Accepted May 28, 2024,

Published Jun 19, 2024

Postal address Av. Eyzaguirre 2061, Puente Alto, Santiago, Chile

MAIN MESSAGES

- Multicentric reticulohistiocytosis is a rare non-Langerhans cell histiocytosis of unknown etiology.
- Only approximately 300 cases have been described in the literature.
- There are very few reported cases of the association between reticulohistiocytosis and breast cancer.
- The association of this disease with breast cancer in our patient exemplifies the importance of neoplastic search in this disease.

systemic corticosteroids, immunosuppressants (e.g., cyclophosphamide, chlorambucil, and methotrexate), and anti-TNF- α biologics (e.g., etanercept and infliximab) are used [1]. Bisphosphonates have demonstrated efficacy in both skin and joint involvement and can be used as monotherapy or combination therapy [1,2]. Cutaneous reticulohistiocytoma can be surgically removed with a low risk of recurrence [2].

This paper presents a rare case of multicentric reticulohistiocytosis associated with breast cancer.

CASE REPORT

A 76-year-old female patient with a history of chronic non-alcoholic liver disease presented with asymptomatic skin lesions in the abdomen of three months duration adjacent to a cholecystectomy scar. Physical examination revealed sagittal abdominal scarring and two well-demarcated purplish erythematous nodular erythematous lesions bordering the scar (Figure 1). No clinical signs of joint involvement were observed. Dermatoscopic examination of the lesion showed an erythematous-violaceous background, with orange areas associated with a whitish veil, bright white structures, desquamation, diffuse peripheral hyperpigmentation (Figure 2A and B), and superficial erosion (Figure 2B).

Dermoscopy shows papules with an erythematous-violaceous background, with orange areas. Associated with a whitish veil, there are white-glossy structures, desquamation, diffuse peripheral hyperpigmentation (Figure 2A and B), and superficial erosion (Figure 2B).

The two abdominal lesions found were biopsied. Histopathological examination showed a nodular and perifollicular inflammatory infiltrate with histiocytes and some multinucleated giant cells with granular eosinophilic and "frosted" cytoplasm associated with lymphocytes, neutrophils and plasma cells (Figure 3A and 3B). An immunohistochemical study showed that histiocytic cells were CD68 (+), CD1a (-), S100 protein (-), and CD34 (-) (Figure 3C). The morphological and immunohistochemical findings were compatible with multicentric reticulohistiocytosis.

As multicentric reticulohistiocytosis may be a paraneoplastic phenomenon, FDG-PET/CT was performed to detect possible occult malignancies. The resulting image showed an abnormal uptake of fluorodeoxyglucose in the left breast. Elevated fluorodeoxyglucose uptake was also observed in the left axillary lymph nodes, which we considered a sign of possible malignancy. Mammography showed microcalcifications as BI-RADS 4B

breast. A breast tissue biopsy was performed, which detected a ductal breast carcinoma.

Three months after surgical excision of the skin lesions of multicentric reticulohistiocytosis, recurrence of the lesions with similar characteristics was observed.

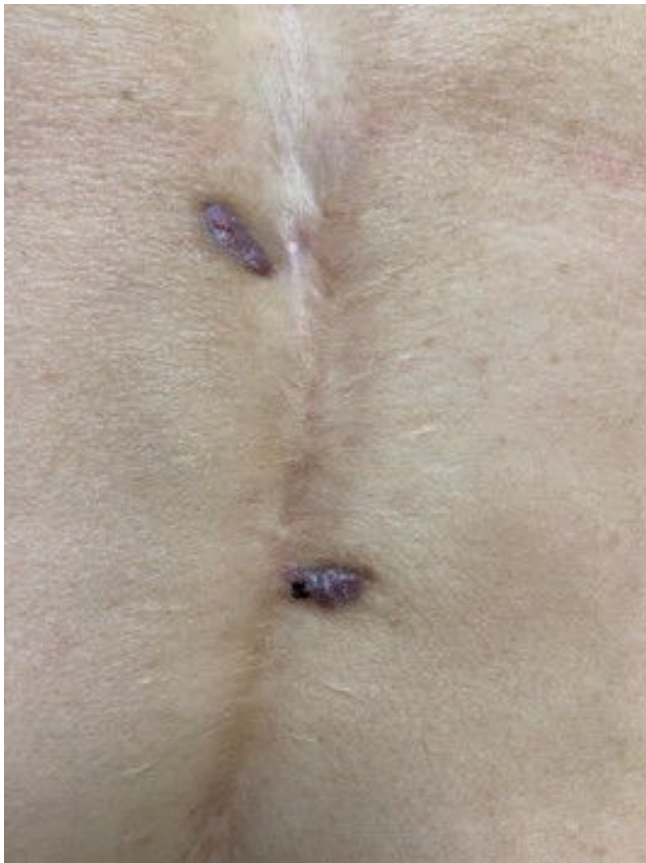
The patient underwent left partial mastectomy and axillary lymphadenectomy, followed by radiotherapy and tamoxifen therapy. Twelve months after surgery, partial regression of multicentric reticulohistiocytosis was observed, with no recurrence of breast cancer. Regular follow-up appointments were made to monitor the lesions. After two years of regular check-ups, the lesions have not recur.

DISCUSSION

Multicentric reticulohistiocytosis is a rare disease with a higher prevalence in women and is strongly associated with malignant neoplasms [7]. Although the pathophysiology is unknown, multicentric reticulohistiocytosis is considered to have an immunological basis [2,3]. It is proposed that an aberrant proliferation of histiocytes leads to the release of cytokines, interleukin-1, 6, 12, and tumor necrosis factor α , generating a constant inflammatory response over time [2,3]. The role of histiocytes in pathophysiological mechanisms such as tissue repair, immune response, and the development of neoplasms supports this theory [3].

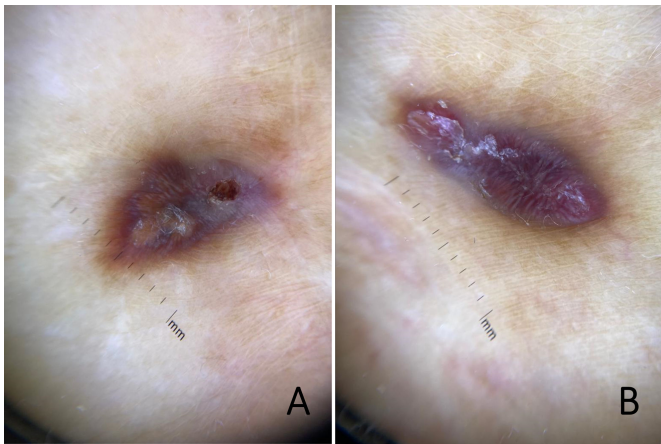
We present the case of a patient with multicentric reticulohistiocytosis in whom histological examination of the lesions clarified the diagnosis and subsequent search for occult neoplasm, detecting a ductal breast carcinoma. Multicentric reticulohistiocytosis is characterized by cutaneous involvement consisting of multiple brownish/reddish cutaneous papules and nodules observed in the patient's abdominal region. Dermoscopy was helpful in the diagnosis, showing yellow/orange spots highly suggestive of histiocytic infiltrate in the dermis [1]. Histologically, multicentric reticulohistiocytosis consists of multinucleated giant cells and eosinophilic cytoplasm, which were present in our patient. [1–10]. This case suggests that it is essential to actively search for neoplasms targeted according to age range and sex. FDG-PET/CT was requested, as it provides crucial information about inflammatory or granulomatous processes, including tumors [1,7]. This examination showed abnormal uptake in the left breast, and mammography showed BI-RADS 4B microcalcifications. A breast biopsy revealed ductal breast carcinoma. On this occasion, surgical removal of the skin lesions was unsuccessful. However, after

Figure 1. Two purplish papules bordering an abdominal scar from cholecystectomy.



Source: Images obtained by the authors of this study.

Figure 2. Papules with diffuse peripheral hyperpigmentation and superficial erosion.



Source: Images obtained by the authors of this study.

mastectomy, radiotherapy, and tamoxifen, no recurrence of both breast cancer and multicentric reticulohistiocytosis lesions was evident at a two-year follow-up. A similar case was reported by Dell'Antonia et al. [1].

This case illustrates the importance of early detection of suspicious lesions of multicentric reticulohistiocytosis and

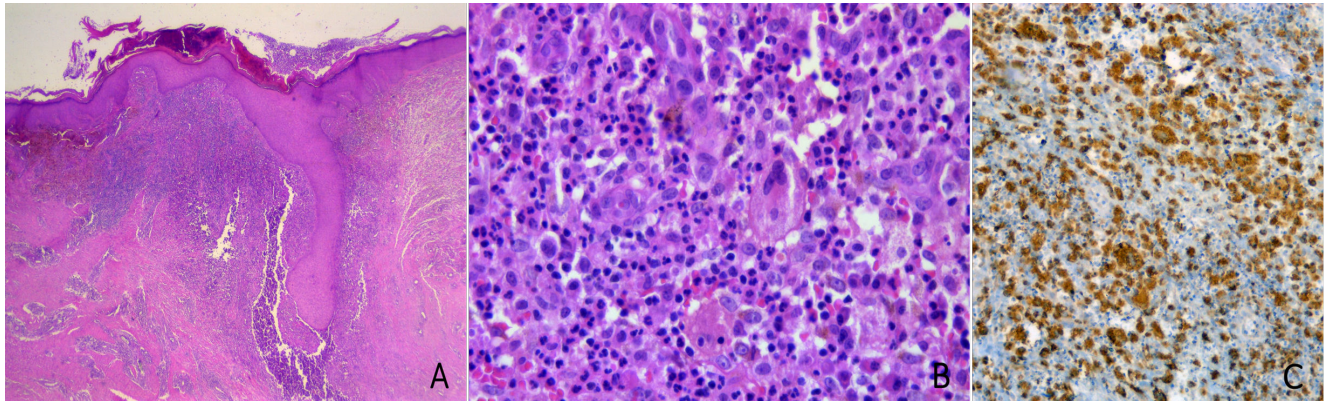
treatment accordingly. Because it is a disease with an unpredictable course, regular follow-up of the case is recommended to monitor for the development or recurrence of neoplasms.

Figure 3. Histopathology of skin lesion.

A. Image at low magnification corresponding to the superficial nodular and perifollicular infiltrate (H-E, original magnification 40x).

B. Cellular detail of the infiltrate, with histiocytic cells and multinucleated giant cells, with granular and eosinophilic cytoplasm, intermixed with lymphocytes, neutrophils, and plasma cells (H-E, original magnification 400x).

C. Immunohistochemical study showed that the histiocytic cells are positive for CD68. The rest of the immunohistochemical study was negative for CD1a, S100 protein, and CD34.



Source: Images obtained by the authors of this study.

CONCLUSIONS

Multicentric reticulohistiocytosis is a rare inflammatory disease of unknown etiology, characterized by cutaneous, joint, and visceral manifestations. Due to its high association with neoplasms, radiological study is suggested according to age and sex. Because it is a disease with an unpredictable course, regular follow-up is recommended to monitor the development or recurrence of neoplasms. Although no standardized treatment exists, early detection and treatment is essential to prevent disease progression.

Contributor roles SPP: Literature search and drafting of the manuscript. GNE: Data collection and critical revision of the manuscript. CBH: Critical review of the literature and drafting of the manuscript. CP: Data collection, contribution, and description of histopathological images.

Competing interests The authors declare that there are no conflicts of interest in this manuscript.

Funding There was no external funding for this study.

Language of submission Spanish.

Peer review and provenance Not commissioned. Externally peer-reviewed by two reviewers, double-blind.

REFERENCES

- Dell'Antonia M, Atzori L, Pilloni L, Ferrelli C. Multicentric reticulohistiocytosis revealing breast cancer: Report of a case with dermoscopic, radiological and therapeutic aspects. *Australas J Dermatol*. 2021;62: 527–529. <https://doi.org/10.1111/ajd.13687>
- Ramos EAB, Almánzar FEC, Guzmán E, Martínez D, Nanita EF, Arenas R. Reticulohistiocytosis multicéntrica: reporte de caso. *Dermatol Cosmet Med Quir*. 2020;18: 108–110. <https://www.medigraphic.com/pdfs/cosmetica/dcm-2020/dcm202g.pdf>
- Figueroa P, de Diego MC, Busso C, Valdez R, Anaya J. Reticulohistiocytosis cutánea difusa. *Dermatol Arg*. 2019;25: 69–71. <https://www.dermatolarg.org.ar/index.php/dermatolarg/article/view/1885>
- Sanchez-Alvarez C, Sandhu AS, Crowson CS, Wetter DA, McKenzie GA, Lehman JS, et al. Multicentric reticulohistiocytosis: the Mayo Clinic experience (1980-2017). *Rheumatology (Oxford)*. 2020;59: 1898–1905. <https://doi.org/10.1093/rheumatology/kez555>
- Patel S, Alhaji M, Brimhall C. A Novel Case of Multicentric Reticulohistiocytosis Associated with Renal Cell Carcinoma Successfully Treated with Infliximab and Methotrexate. *Case Rep Dermatol*. 2023;15: 10–16. <https://doi.org/10.1159/000528254>
- Fronek L, Bindernagel R, Segars K, Miller R. Multicentric reticulohistiocytosis masquerading as cutaneous connective tissue disease. *Dermatol Online J*. 2021;27: 1–5. <http://doi.org/10.5070/D3273052766https://doi.org/10.5070/D3273052766>
- Asano T, Suzutani K, Watanabe A, Honda A, Mori N, Yashiro M, et al. The utility of FDG-PET/CT imaging in the evaluation of multicentric reticulohistiocytosis: A case report. *Medicine (Baltimore)*. 2018;97. <https://doi.org/10.1097/MD.00000000000011449>
- Serra-García L, Morgado-Carrasco D. Manifestaciones cutáneas de las histiocitosis. *Piel*. 2021;36: 165–174. <https://doi.org/10.1016/j.piel.2020.05.013>
- Mariotti EB, Corrà A, Lemmi E, Laschi L, Aimò C, Quintarelli L, et al. Multicentric Reticulohistiocytosis Associated with an Early Form of Systemic Lupus Erythematosus: A Case Report of A Rare Disease, with Mini Review of the Literature. *J Clin Med*. 2022;11. <https://doi.org/10.3390/jcm11216529>
- Caicedo OA, Medina MA, Caracciolo JÁ, Papasidero SB. Reticulohistiocytosis multicéntrica: una gran simuladora

dentro de la Reumatología. Rev Argent Reumatol. 2022;33:
39–42. <https://doi.org/10.47196/rar.v33i1.651>

Reticulohistiocitosis multicéntrica reveladora de cáncer de mama ductal *in situ*: reporte de caso con aspectos dermatoscópicos e histopatológicos

RESUMEN

La reticulohistiocitosis multicéntrica es una enfermedad inflamatoria, una histiocitosis de células no Langerhans, poco frecuente y de etiología desconocida. Se clasifica como multicéntrica al presentar compromiso multisistémico. La enfermedad afecta predominantemente a la piel y las articulaciones, pero es posible la afectación visceral. Las manifestaciones cutáneas se caracterizan por múltiples nódulos y pápulas de color eritemato-marronáceas, pruriginosas en la cara, manos, cuello y tronco. Se asocia a enfermedades autoinmunes y neoplasias malignas, observándose entre el 20 y el 30% de los pacientes con reticulohistiocitosis multicéntrica. Su diagnóstico se realiza sobre la base de la histopatología de tejidos afectados. Al ser una enfermedad poco reportada, no existe tratamiento estandarizado. Se reporta un caso de reticulohistiocitosis multicéntrica como manifestación paraneoplásica a un cáncer ductal de mama, siendo tratadas con éxito, sin recidivas luego de dos años de seguimiento. Pocos casos se han reportado en la literatura de reticulohistiocitosis multicéntrica asociado a cáncer mamario.



This work is licensed under a Creative Commons Attribution 4.0 International License.