




# Late diagnosis of disseminated tuberculosis: A case report

Luis Alejandro Rodriguez-Hidalgo, Dr<sup>a\*</sup> , Diana Ruiz-Caballero<sup>a, b</sup> , Amalia Vega-Fernandez<sup>a</sup> 

<sup>a</sup>Escuela Profesional de Medicina, Facultad de Ciencias de la Salud, Universidad César Vallejo, Trujillo, Perú; <sup>b</sup>Departamento de Medicina, Hospital Regional Docente de Trujillo, Trujillo, Perú

## ABSTRACT

**INTRODUCTION** The lungs are most commonly involved in tuberculosis, but infection can involve other organs through lymphohematogenous dissemination. The clinical presentation of disseminated tuberculosis is variable. Diagnosis is challenging as 50% of patients present a late diagnosis because clinical manifestations are diverse and subacute, and microbiological testing relies on invasive procedures for mycobacterial culture and supportive histopathology

**CASE REPORT** A 30-year-old male patient, deprived of his liberty, with no co-morbidities, was admitted to the hospital for severe pain in the left wrist, with a previous history of having received systemic glucocorticoids for seven months. He developed clinical symptoms of pulmonary tuberculosis in the pleura, in the joint of the left wrist, and the left testicle and tests confirmed the presence of *M. tuberculosis*. He underwent surgery on the wrist and testicle and was also treated for susceptible tuberculosis. Concomitant sequelae of iatrogenic Cushing's disease, chronic anemia, and chronic inactive proctitis were diagnosed.

**CONCLUSIONS** Diagnosing disseminated tuberculosis was challenging due to the non-specific clinical picture, limitations of confirmatory diagnostic tools, and timely specialized evaluations. Prolonged use of systemic corticosteroids may have played a role in the dissemination of tuberculosis.

**KEYWORDS** Disseminated tuberculosis, multisystem, miliary tuberculosis, diagnosis

## INTRODUCTION

The lungs are the most common site of infection in tuberculosis, accounting for almost 70% of cases. Infection can also involve other organs through lymphohaematogenous dissemination [1,2]. Extrapulmonary sites include lymph nodes, pleura, kidneys, spine, joints, brain, meninges, peritoneum, intestine, liver, testis, ovaries, fallopian tubes, eyes (choroid) and pericardium [2,3]. Predisposing factors for disseminated TB include elderly patients, people with human immunodeficiency virus infection, alcohol abuse, diabetes, chronic liver or kidney failure, organ transplantation, immunosuppressive drugs, prolonged corticosteroids, pregnancy, and symptomatic tuberculosis lasting more than 12 weeks [4–6]. Disseminated tuberculosis is a progressive and potentially fatal

disease. Tuberculosis spreads through lymphohaematogenous dissemination of *Mycobacterium tuberculosis* bacillus from primary tuberculosis or progression of untreated primary tuberculosis [1,6]. Of all tuberculosis cases, only 1-2% are of the disseminated [7].

The clinical presentation of disseminated tuberculosis is variable. Symptoms include sub-acute or chronic constitutional symptoms such as fever, weight loss, and night sweats, but may present as multi-organ failure. The duration of symptoms and signs prior is variable, and more than 50% of patients seek medical help several months after the onset of symptoms [8–12].

Diagnosis remains challenging because clinical manifestations are diverse, and microbiological testing relies on invasive procedures for mycobacterial culture and supportive histopathology. In addition, these tests are not available in most healthcare facilities [13].

The present report aims to portray the importance of timely diagnosis of tuberculosis to prevent multi-organ involvement with severe sequelae or death.

\* Corresponding author lrodriguezhi14@ucvvirtual.edu.pe

**Citation** Rodriguez-Hidalgo LA, Ruiz-Caballero D, Vega-Fernandez A. Late diagnosis of disseminated tuberculosis: A case report. Medwave 2024;24(7):e2917

**DOI** 10.5867/medwave.2024.07.2917

**Submitted** Feb 6, 2024, **Accepted** Jul 10, 2024,

**Published** Aug 28, 2024

**Postal address** Urbanización Los Portales del Golf Víctor Larco, Trujillo, Perú

## MAIN MESSAGES

- Disseminated tuberculosis is a life-threatening condition, especially if diagnosis and treatment are delayed.
- Only 1 to 2% of tuberculosis cases are disseminated.
- Diagnosing disseminated tuberculosis is challenging, as adequately selected specimens for bacteriological and molecular testing are needed.
- We present a case report of disseminated tuberculosis, which may shed some light on the approach on patient management.
- Early diagnosis of disseminated tuberculosis prevents death and disabling sequelae.

## CASE REPORT

Male, 30 years old, single. Person deprived of liberty (prisoner). He was admitted for emergency hospitalization to the traumatology department of the Hospital Regional Docente de Trujillo on 15 April 2023 for presenting intense pain and signs of phlogosis in the left wrist.

The patient reported that in April 2022, he presented with a sensation of heaviness and numbness in her left wrist. Within a few hours, pain began to set in, and pain increased with its volume. He did not receive any treatment. Approximately one month later, he was treated by prison medical staff with the hypothesis of deep venous insufficiency. On that occasion, he was administered enoxaparin subcutaneously every 12 hours for a month, showing a slight improvement. As the discomfort persisted, a wrist fracture was suspected.

For this reason, he was taken to the "bonesetter" (empirical person) to "set" the fracture, who immobilized him with splints and bandages. From that moment on, the increase in volume of the wrist joint began to become more noticeable, and the pain became more intense, adding deformity and functional limitation. In August 2022, he began to feel a "lump" in the perianal area, which he played down. He was diagnosed with an anorectal fistula of "undefined" infectious cause, as bacteriological tests were not performed. The approach was to perform a fistulectomy. In October 2022, he attended the prison infirmary, where he was initially administered once daily dexamethasone plus diclofenac sodium via intramuscular route. Due to persistent pain, the dose was increased to every 12 hours for three months. This was the only way to control the pain. The patient continued to self-medicate with dexamethasone and diclofenac tablets orally every 12 hours for four months, during which time he presented weight gain of 12 kilos and signs compatible with iatrogenic untreated Cushing's syndrome.

In February 2023, he began to notice a progressive increase in the volume of his left testicle without receiving medical attention. At the beginning of March, he was diagnosed with pulmonary tuberculosis at the penitentiary establishment with a positive smear test. No chest X-ray examination was carried out.

On 8 March 2023, the first phase of treatment for tuberculosis with a sensitive schedule was started. For two months, he was given a daily dose of 300 milligrams of isoniazid, 600 milligrams of rifampicin, 1600 milligrams of ethambutol, and 1875 milligrams of pyrazinamide.

In mid-April, he was transferred from the prison to the outpatient trauma clinic of the Regional Teaching Hospital of Trujillo and immediately transferred to the emergency department for hospitalization.

On admission, he presented with normal vital functions and was in apparently fair general condition. Oxygen saturation (SaO<sub>2</sub>) was 97% room air. He had a height of 1.75 meters, a weight of 65 kilograms, and a body mass index (BMI) of 21.

On preferential examination, he had linear purplish striae in the subcutaneous cellular tissue on the forearms and thighs (Figure 1). The head, neck, thorax, and abdomen were unremarkable. In the genitourinary area, the left testicle showed signs of flogosis, as did the left wrist. The left wrist also showed deformity and pain on digit pressure, and a "soft collection" measuring four by 4 centimeters was palpated (Figure 2), with limitation of joint movements.

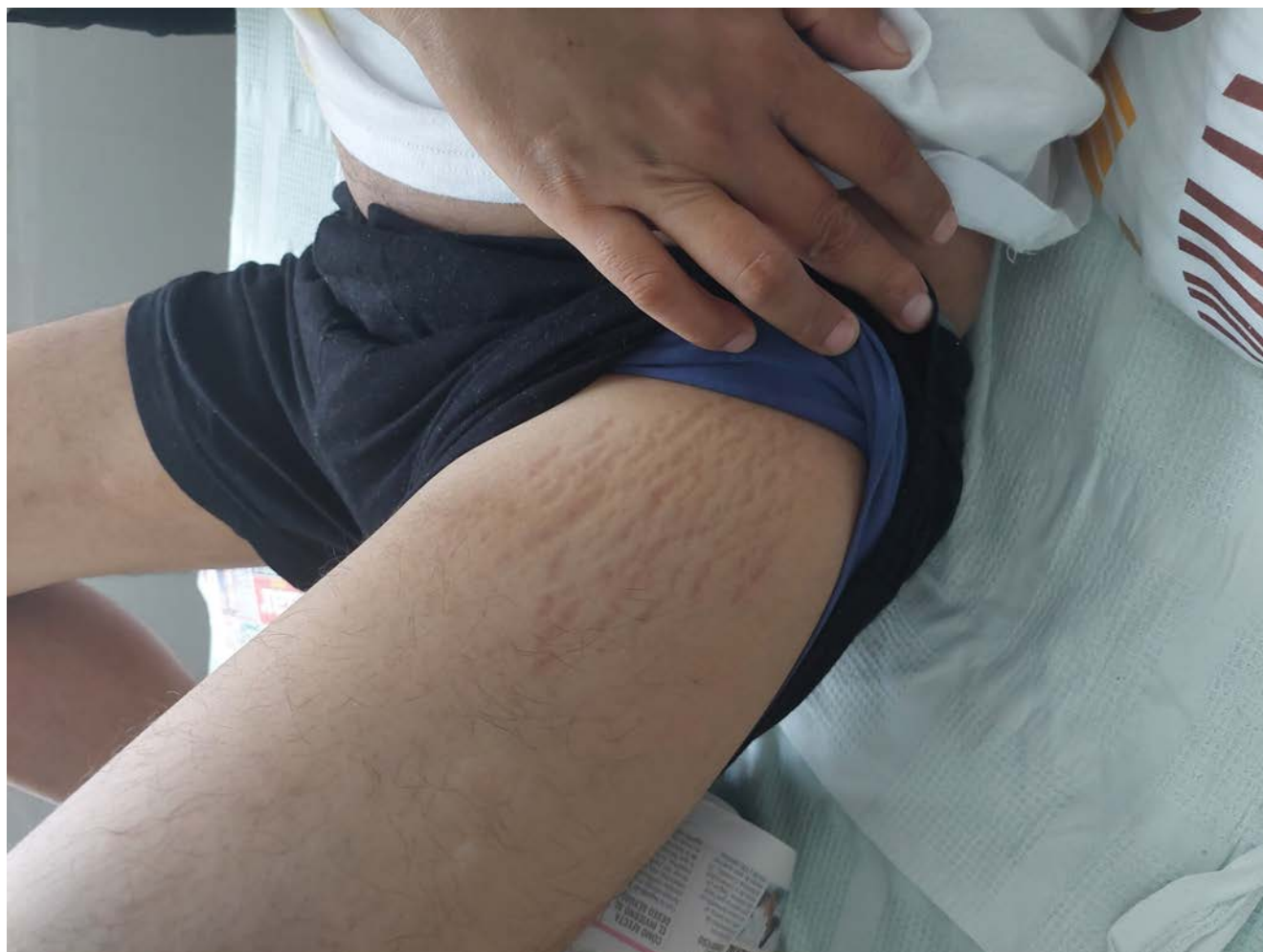The initial presumptive diagnoses were fracture of the left ulna and distal radius, osteomyelitis of the left wrist, and pulmonary tuberculosis under treatment.

During his hospitalization in the traumatology department, he was evaluated by the pulmonology department, which indicated that he should continue treatment for tuberculosis. He was also evaluated by the urology department, which requested testicular, renal, bladder, and prostate ultrasound scans, as well as smear microscopy and urine culture for *Mycobacterium tuberculosis*. Ten days later, he was re-evaluated by the pneumology service, referring to joint problems in the left wrist and pain, plus increased volume in the left testicle.

At this point, the patient had a diagnostic presumption of disseminated tuberculosis consisting of pulmonary, joint, and testicular involvement. Consequently, it was indicated to continue with antituberculosis treatment and to request smear microscopy, smear culture, and rapid sensitivity tests (real-time polymerase chain reaction) of secretion from wrist lesions and urine. Re-evaluation by urology was suggested, in addition to urgent surgery of the left wrist joint.

On 4 May, the patient underwent trauma surgery. The procedure included drainage of the left wrist abscess and surgical cleaning. Liquefied viscoelastic tissue and distorted, highly vascularised bone tissue were reported with no foul odor or purulent discharge. In addition, samples were taken from the lesion for bacteriological studies. The pathology report of the

**Figure 1.** Subcutaneous striae, sequelae of iatrogenic Cushing's disease.



Source: Recorded by the authors of this study.

bone biopsy concluded with chronic osteomyelitis. The results of the tissue sample from the left wrist smear were positive.

After re-evaluation by urology, acute orchiepididymitis was diagnosed, ruling out epididymal tuberculosis. Treatment indicated 500 milligrams of levofloxacin every 24 hours orally for seven days, 15 milligrams of meloxicam orally for seven days, scrotal suspension, and re-evaluation at the end of treatment.

The urology department re-evaluated the case at the end of the indicated treatment, performing a puncture and aspiration of the left testicular abscess (Figure 3). The following day, the result of the secretion analysis showed a positive smear test. With the diagnosis of testicular tuberculosis, it was decided to perform a radical left orchidectomy (Figure 4). Tissue samples were sent for anatomical pathology and bacteriology studies. The anatomical pathology report concluded findings in the scrotum with chronic active inflammation, microabscesses, and non-caseating granulomas. In addition, areas of edema and interstitial vascular congestion were present in the testis.

The gastroenterology unit also performed proctosigmoidoscopy. This recorded findings of entero-cutaneous anorectal

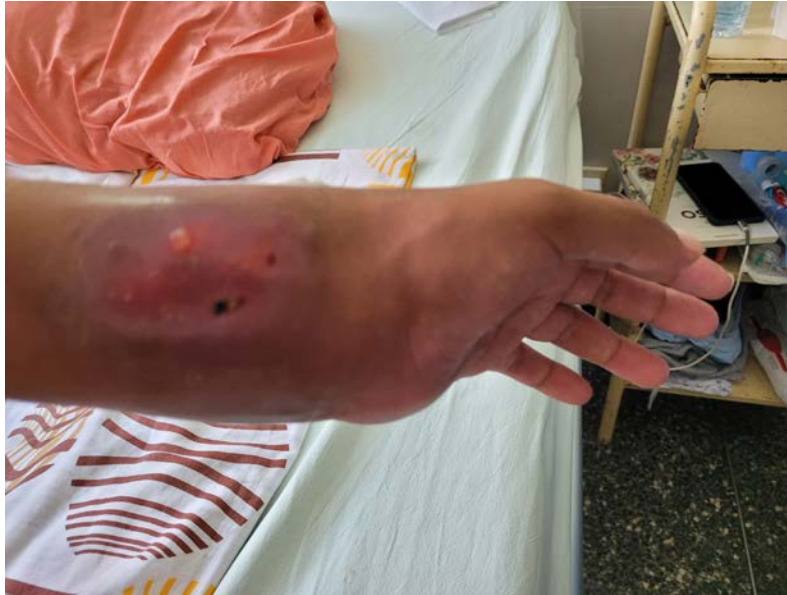fistula. The biopsy report of the anal region concluded chronic inactive proctitis. The smear of secretion from the anorectal fistula was negative. The unit recommended symptomatic treatment and outpatient control.

The pneumology department indicated continuing the second phase of antituberculosis treatment with 300 milligrams of isoniazid and 600 milligrams of rifampicin, both administered daily for ten months. Finally, the scheme was structured in the first phase, which consisted of two months of isoniazid, rifampicin, ethambutol, and pyrazinamide daily. In the second phase, isoniazid and rifampicin for ten months, also daily (2HREZ /10HR), according to the Technical health standard for the comprehensive care of the person affected by tuberculosis, family and community 2023 [3].

With these findings, the patient was transferred to the infectious disease department for further treatment.

Other drugs the patient received were oxacillin at a dose of 2 grams intravenous every 6 hours for 21 days, 100 milligrams of intravenous ketoprofen every 12 hours for seven days, 100

Figure 2. Left wrist injury.



Source: Recorded by the authors of this study.

Figure 3. Aspiration discharge from left testicular abscess.



Source: Recorded by the authors of this study.

milligrams of intravenous tramadol conditioned to the presence of pain once a day for one month.

At discharge, the patient was diagnosed with disseminated tuberculosis (pulmonary, bone, and testicular tuberculosis), with sequelae of iatrogenic Cushing's disease and anorectal fistula, along with chronic inactive proctitis and mild chronic anemia.

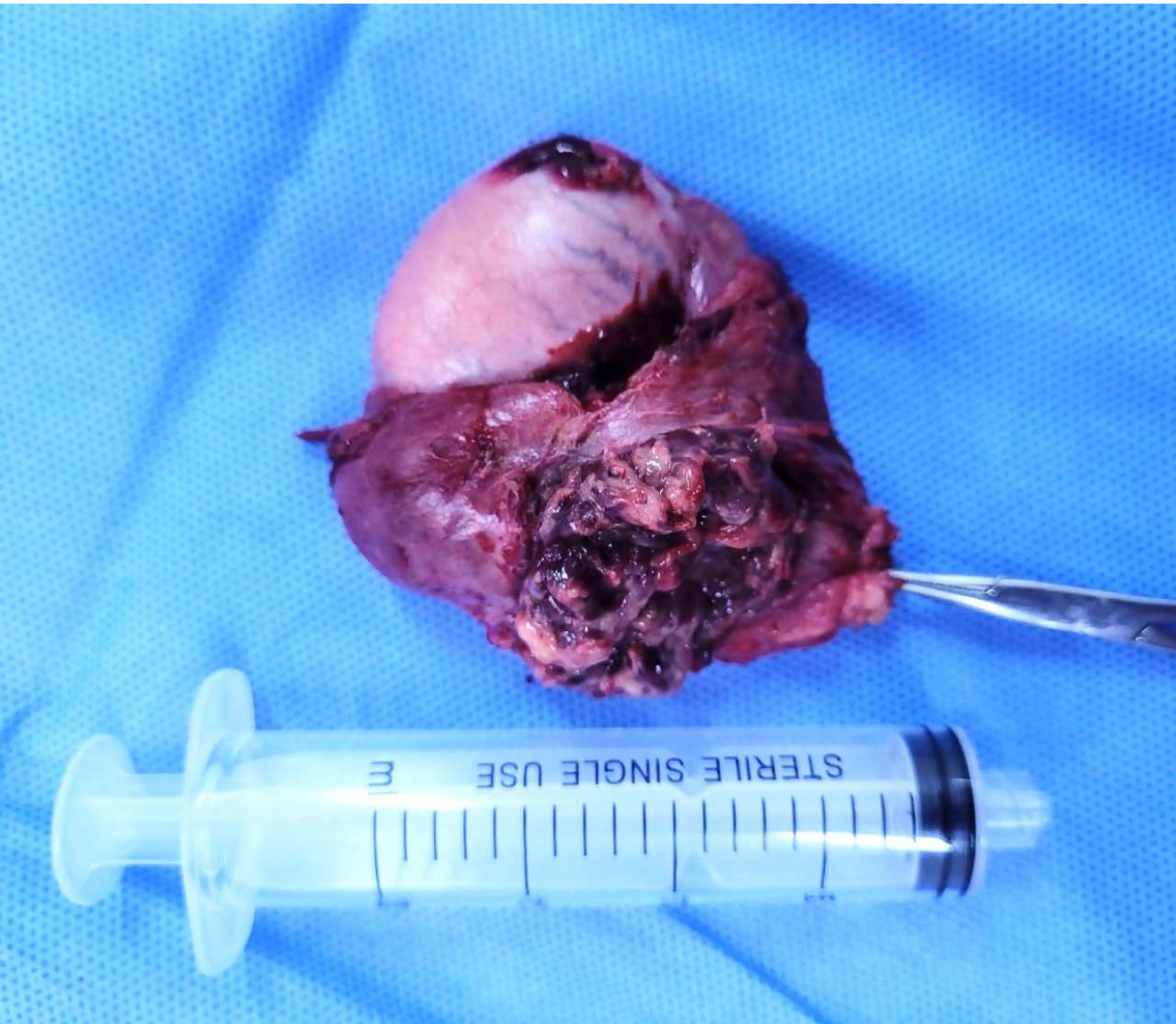Subsequently, in July 2023, he was checked by the infectious diseases department, which reported an improvement in the clinical picture of disseminated tuberculosis.

In November 2023, he was monitored by urology, traumatology, and pneumology. Urology reported the absence of the left testicle and the right testicle without alterations, with a good evolution. Traumatology, with the support of radiographic

studies of the wrist, reported a good evolution of the tuberculous infection (Figure 5), indicating that it did not merit surgical intervention (arthrodesis), as there had been an ankylosis of the carpal joint (Figure 6). Nevertheless, they recommended avoiding excessive physical activity with the hand and wrist. For its part, pulmonology concluded that the patient adhered to the treatment did not present significant discomfort, and resulted in a good clinical, bacteriological, and radiological evolution. For these conclusions, the service relied on the results of the radiological study of the chest (Figure 7), the smear tests, and the negative sputum culture for acid-alcohol-resistant bacilli. Consequently, discharge was indicated upon completion of the antituberculosis treatment regimen.



Figure 4. Radical left orchidectomy.



Source: Recorded by the authors of this study.

The patient reported a significant improvement in his mood due to the remission of respiratory and testicular complaints, mainly because his self-care dependency was primarily resolved with the improvement of the left wrist injury. However, the patient stated that he was aware that he would be left with permanent functional limitations.

Table 1 summarises the main symptoms and signs, as well as the examination and treatments performed.

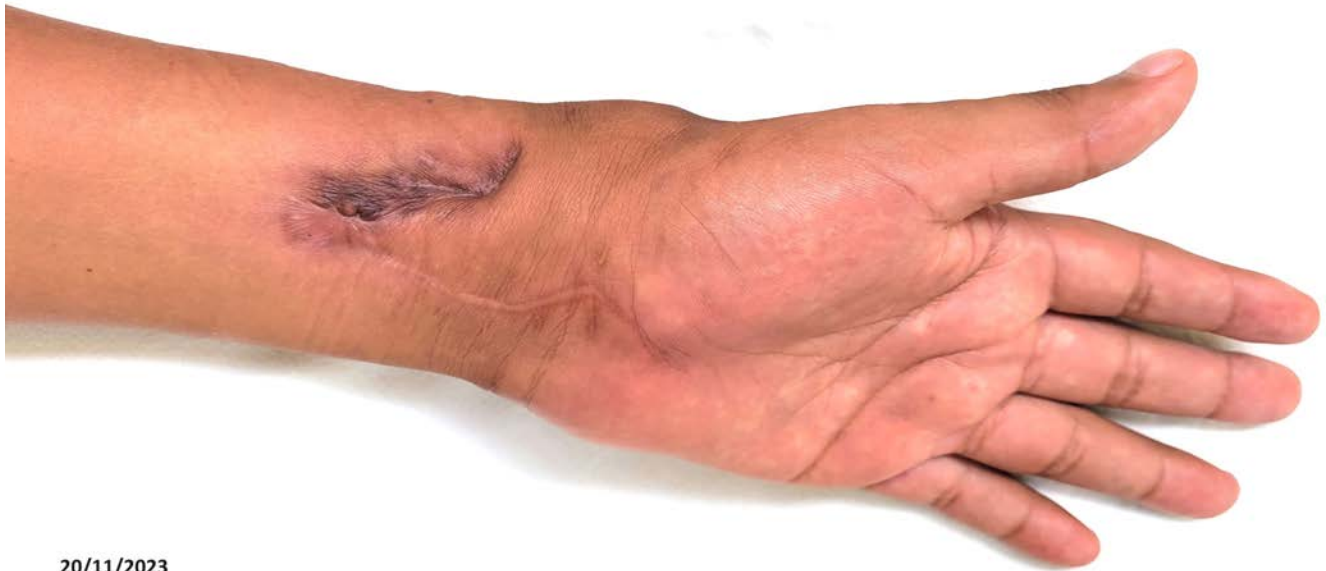**DISCUSSION**

Disseminated tuberculosis is the presence of two or more non-contiguous sites resulting from hematogenous dissemination of *Mycobacterium tuberculosis*. It occurs due to progressive primary infection or by reactivating a latent focus with subsequent dissemination [14]. It is rarely iatrogenic in origin

[15]. Our clinical case fulfills these criteria to be considered disseminated tuberculosis since the presence of *Mycobacterium tuberculosis* was confirmed in the lungs, the wrist joint, and the testicle, in addition to the residual pachypleuritis secondary to pleural tuberculosis observed in the final radiological study. We could infer that the entero-cutaneous anorectal fistula was also caused by tuberculous infection, considering it is a frequent presentation [16,17]. This is despite the fact that the detection of *Mycobacterium tuberculosis* complex was not confirmed by specific tests, and only residual lesions were found due to previous surgical treatment.

Disseminated tuberculosis is a life-threatening condition, significantly if diagnosis and treatment are delayed [14,16]. The diagnosis was challenging in this case due to its non-specific clinical picture and the paucity of tools available to confirm

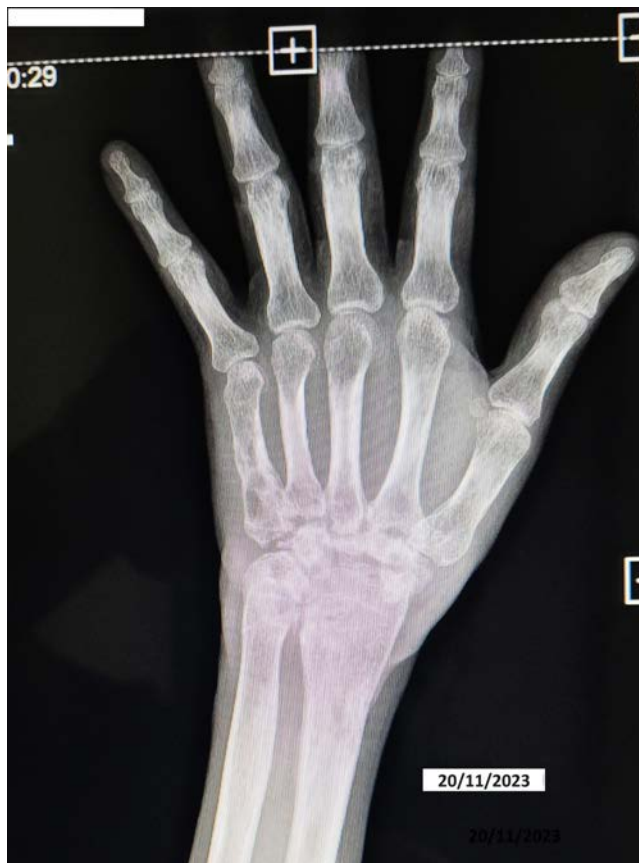Figure 5. Left wrist injury sequelae.



20/11/2023

Source: Recorded by the authors of this study.

Figure 6. Sequelae of articular tuberculosis, absence of the carpus.



Source: Recorded by the authors of this study.

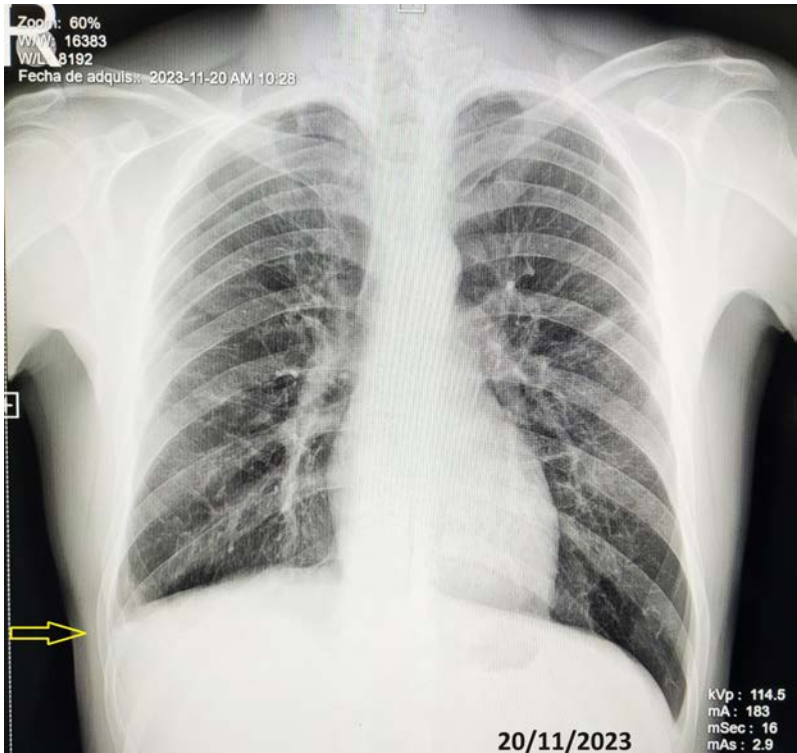
the laboratory diagnosis. The low sensitivity of smear microscopy compounds is due to the time-consuming cultures and molecular tests unavailable in most facilities.

The subtle and non-specific clinical presentation of the present case, the limitation of confirmatory diagnostic tools, and the difficulty in getting out of prison for timely specialized evaluations would have led to this disorder of disseminated TB being underestimated.

The incidence of disseminated tuberculosis is not yet known precisely. However, among immunocompetent adults, it is estimated that this group accounts for less than 2% of all tuberculosis cases and up to 20% of all extrapulmonary tuberculosis cases [15]. Disseminated tuberculosis is a significant cause of morbidity and mortality in developing countries. It has become more frequent in different age groups due to several risk factors. These include human immunodeficiency virus infection, the use of biologic drugs, immunosuppressants and corticotherapy, alcoholism, chronic liver disease, chronic hemodialysis, diabetes mellitus, malignant neoplasms, and silicosis [14–20]. In our case, the patient was exposed to systemic glucocorticoids inappropriately (as an analgesic) and prolonged. This caused an alteration in his immune response and, consequently, would have favored the dissemination of *Mycobacterium tuberculosis* to different organs (pulmonary, pleural, bone, testicular, and ano-rectal).

The mechanism of *Mycobacterium tuberculosis* dissemination is not well understood [21]. One proposed mechanism is that tuberculous infection spreads through a pulmonary vein after eroding the alveolar epithelial cell layer [21,22]. When the bacteria reach the left side of the heart and enter

**Figure 7.** Pleural tuberculosis sequelae (pachypleuritis), right phrenic costophrenic angle obturation (arrow). No lesions in lung parenchyma.



Source: Recorded by the authors of this study.

**Table 1.** Summary of main symptoms, signs, examinations, surgical, and pharmacological treatments.

Signs and symptoms	Complementary studies and their results	Invasive diagnostic procedures and surgical treatments	Pharmacological treatment
Productive cough	Positive sputum smear microscopy.	Drainage and surgical cleaning and bone biopsy of left wrist bone	Treatment for susceptible tuberculosis
Numbness in left wrist	X-ray of left wrist: fracture of ulna and radius and signs of osteomyelitis.	Puncture and aspiration of a left testicular abscess	Adjuvant antibiotic treatment with oxacillin Analgesics
Phlogosis of the left wrist	Left wrist bone biopsy: chronic osteomyelitis	Total left orchidectomy	
Deformity and functional limitation of left wrist	Positive tissue smear of left wrist: positive	Proctosigmoidoscopy and anal biopsy	
The sensation of a "lump" in the perianal region	Positive bacilloscopy of left testicular abscess		
Anorectal fistula	Biopsy of the left testicle: microabscesses and non-caseating granuloma.		
Iatrogenic Cushing's syndrome	Bacilloscopy of anorectal fistula: negative		
Enlargement of the left testicle	Chest X-ray: residual pachypleuritis post pleural tuberculosis		

Prepared by the authors of this study.

the circulatory system, they multiply and infect extrapulmonary organs, causing disseminated systemic tuberculosis. Also, mycobacteria can damage the cells lining the alveoli and enter the lymph nodes. From there, it enters the systemic venous blood and circulates back to the lung through the right side of the heart, producing disseminated pulmonary tuberculosis with

a miliary appearance [21,22]. The two forms of dissemination can occur independently or together.

Dissemination of tuberculosis rarely occurs as an iatrogenic infection. A few cases have been published describing tuberculosis dissemination following surgical intervention [15,23–27]. A non-health professional ("bonesetter")'s empirical



manipulation of the wrist joint could be considered an initial or primary iatrogenic infection. This is because he presented with non-specific symptoms and signs in the left wrist long before the clinical presentation of tuberculosis in the lungs and testis.

Histological examination revealed microscopically tuberculous granulomas with or without central caseification. Sometimes, alcohol-resistant bacilli can be found within macrophages or in areas of caseification [17,28]. These findings are consistent with those described in the reports of the anatomy-pathology studies performed on our patient.

Acid-fast smears, real-time polymerase chain reaction, mycobacterial culture, and histology are needed to confirm the diagnosis in patients with suspected disseminated tuberculosis [14]. Nucleic acid amplification testing by real-time polymerase chain reaction has been used as a rapid diagnostic tool for tuberculosis, as it detects *Mycobacterium tuberculosis* complex directly from patient samples in only two hours [29]. Therefore, all samples from our patient, both secretions and tissue, obtained by biopsy and surgical excision, were sent to the mycobacteria laboratory. These samples were used for smear microscopy, culture for mycobacterium tuberculosis, and molecular biology testing (real-time polymerase chain reaction for tuberculosis). Positive results were obtained, proving the presence of the bacillus *Mycobacterium tuberculosis*.

Other rapid and non-invasive tests have also been used on samples other than sputum. This is because measuring biomarkers such as adenosine deaminase and interferon is inconclusive in cases of extrapulmonary tuberculosis despite its validating and confirmatory role [30–35].

Histopathology remains an essential method for diagnosing tuberculosis [3,36]. It is the diagnostic tool that we have also used in the study of wrist joint and testicular lesions, the results of which contributed to the diagnosis of disseminated tuberculosis.

## CONCLUSIONS

The diagnosis of disseminated tuberculosis was difficult due to the non-specific clinical picture. To confirm the occult diagnosis of extrapulmonary presentation, molecular testing, and histology were necessary.

Prolonged use of systemic corticosteroids would have influenced the dissemination of tuberculosis.

The limitation of confirmatory diagnostic tools and specialized evaluations promptly resulted in underestimating the involvement of various organs in tuberculosis.

**Contributor roles** RHLA: conceptualisation, research. RCDC: data acquisition and review. VFAG: writing (review and editing) and methodology.

**Competing interests** The authors declare that they have no conflicting interests.

**Funding** There was no external funding for the development of this work. The publication of the scientific article will be financed by the Universidad César Vallejo.

**Language of submission** Spanish.

**Peer review and provenance** Unsolicited. With external peer review by two peer reviewers, double-blind.

## REFERENCES

1. Crump JA, Ramadhani HO, Morrissey AB, Saganda W, Mwako MS, Yang L-Y, et al. Bacteremic disseminated tuberculosis in sub-saharan Africa: a prospective cohort study. *Clin Infect Dis*. 2012;55: 242–50. <https://doi.org/10.1093/cid/cis409>
2. Ramírez-Lapausa M, Menéndez-Saldaña A, Noguero-Asensio A. Tuberculosis extrapulmonar, una revisión. *Rev esp sanid penit*. 2015;17: 3–11. <https://dx.doi.org/10.4321/S1575-06202015000100002> <https://doi.org/10.4321/S1575-06202015000100002>
3. In: Norma Técnica de Salud para el Cuidado Integral de la Persona Afectada por Tuberculosis, Familia y Comunidad [Internet]. <https://bvs.minsa.gob.pe/local/MINSA/6344.pdf>
4. Romero S, Polanía MD, Prieto C, Zannin Ferrero A, Zuleta Quintero PG, Celis LG. Tuberculosis miliar paucibacilar secundaria al manejo con etanercept en artritis reumatoide. Reporte de caso. *rev colomb neumol*. 33: 19–24. <https://revistas.asoneumocito.org/index.php/rcneumologia/issue/view/40> <https://doi.org/10.30789/rcneumologia.v33.n1.2021.417>
5. Hernández-Solís A, Quintana-Martínez A, Quintanar-Ramírez MI, Álvarez-Maldonado P, Reding-Bernal A. Tuberculosis extrapulmonar: un problema de salud pública. *CIRU*. 2023;91: 131–138. <https://doi.org/10.24875/ciru.21000688> <https://doi.org/10.24875/CIRU.21000688>
6. Meira L, Chaves C, Araújo D, Almeida L, Boaventura R, Ramos A, et al. Predictors and outcomes of disseminated tuberculosis in an intermediate burden setting. *Pulmonology*. 2019;25: 320–327. <https://doi.org/10.1016/j.pulmoe.2018.11.001>
7. Pino-Alfonso P, Hernández-Moreno L, Vega-Rodríguez I. Tuberculosis miliar. *Revista Cubana de Medicina* [Internet]. 2021;60. <https://revmedicina.sld.cu/index.php/med/article/view/2313>
8. Yousef Khan F, Dosa K. Disseminated Tuberculosis among Adult Patients Admitted to Hamad General Hospital, Qatar: A Five Year Hospital Based Study. *Mycobact Dis*. 2016;6: 212. <https://doi.org/10.4172/2161-1068.1000212>
9. Gonzales-Cortiñas M, Román-Abreu A, Borges-Fernández R, Hernández-Niebla L. Tuberculosis Diseminada. Presentación de un caso y revisión de la literatura. *Rev. Med. Clin. Condes*. 2023; 34(5) 376–382. <https://doi.org/DOI:10.1016/j.rmclc.2023.08.003>
10. Ong S, Kibbler J, Maxwell G, Steer J. Disseminated tuberculosis associated with fingolimod treatment in a patient with multiple sclerosis. *BMJ Case Rep*. 2024;17. <https://doi.org/10.1136/bcr-2023-255011>



11. Boushab BM, Basco LK. Miliary tuberculosis and acute respiratory distress syndrome. *J Clin Tuberc Other Mycobact Dis.* 2019;16. <https://doi.org/10.1016/j.jctube.2019.100113>
12. Mert A, Arslan F, Kuyucu T, Koç EN, Yilmaz M, Turan D, et al. Miliary tuberculosis: Epidemiological and clinical analysis of large-case series from moderate to low tuberculosis endemic Country. *Medicine (Baltimore).* 2017;96. <https://doi.org/10.1097/MD.0000000000005875>
13. Arpagaus A, Franzeck FC, Sikalengo G, Ndege R, Mnzava D, Rohacek M, et al. Extrapulmonary tuberculosis in HIV-infected patients in rural Tanzania: The prospective Kilombero and Ulanga antiretroviral cohort. *PLoS One.* 2020;15. <https://doi.org/10.1371/journal.pone.0229875>
14. Khan FY. Review of literature on disseminated tuberculosis with emphasis on the focused diagnostic workup. *J Family Community Med.* 2019;26: 83–91. [https://doi.org/10.4103/jfcm.JFCM\\_106\\_18](https://doi.org/10.4103/jfcm.JFCM_106_18)
15. M S, Yelne S, Chaudhary M, Agrawal A. Unveiling the Silent Invader: A Case Report on Miliary Tuberculosis. *Cureus.* 2023;15: e41817. <https://doi.org/10.7759/cureus.41817>
16. González Díaz D, Herrera-González A, Ortiz-Roque J, del Toro-Pazos MÁ. Miliary tuberculosis, a clinical-radiological finding. About a case. *International Journal of Medical and Surgical Sciences.* 2021;8: 1–7. <https://doi.org/10.32457/ijmss.v8i3.1531>
17. Andrei LS, Andrei AC, Micu A, Marghescu S, "Fundeni", et al. Extrapulmonary Tuberculosis – a Rare Cause of Difficult Evolution in a Case Of Extensive Anoperianal Suppuration. *Rev Med Mod.* 2023;30: 353–356. <https://medicinamoderna.ro/2023-volume-30/2023-issue-4> <https://doi.org/10.31689/rmm.2023.30.4.353>
18. Tsukamoto Y, Kiyasu J, Tsuda M, Ikeda M, Shiratsuchi M, Ogawa Y, et al. Fatal Disseminated Tuberculosis during Treatment with Ruxolitinib Plus Prednisolone in A Patient with Primary Myelofibrosis: A Case Report and Review of the Literature. *Intern Med.* 2018;57: 1297–1300. <https://doi.org/10.2169/internalmedicine.9165-17>
19. Gaifer Z. Epidemiology of extrapulmonary and disseminated tuberculosis in a tertiary care center in Oman. *Int J Mycobacteriol.* 2017;6: 162–166. [https://doi.org/10.4103/ijmy.ijmy\\_31\\_17](https://doi.org/10.4103/ijmy.ijmy_31_17)
20. Mert A, Arslan F, Kuyucu T, Koç EN, Yilmaz M, Turan D, et al. Miliary tuberculosis: Epidemiological and clinical analysis of large-case series from moderate to low tuberculosis endemic Country. *Medicine (Baltimore).* 2017;96. <https://doi.org/10.1097/MD.0000000000005875>
21. Ahmed A, Mohammed S, Sadek M. Miliary Tuberculosis with Paraspinal Collection and Tuberculoma. *J Trop Med Hyg.* 2023;109: 223–224. <https://doi.org/10.4269/ajtmh.23-0083>
22. Vohra S, Dhaliwal HS. Miliary Tuberculosis. In: StatPearls [Internet]. 15 Apr 2023. <https://www.ncbi.nlm.nih.gov/books/NBK562300>
23. Poplin V, Harbaugh B, Salathe M, Bahr NC. Miliary tuberculosis in a patient with end-stage liver disease. *Cleve Clin J Med.* 2020;87: 590–593. <https://doi.org/10.3949/ccjm.87a.19143>
24. Tahir M, Nida A, Qamar S. Hiding in the bone: a case of miliary tuberculosis with bone marrow involvement. *AME Case Rep.* 2018;2. <https://doi.org/10.21037/acr.2018.06.05>
25. Kulchavenya E, Kholobin D, Shevchenko S. Challenges in urogenital tuberculosis. *World J Urol.* 2020;38: 89–94. <https://doi.org/10.1007/s00345-019-02767-x>
26. Mehboob K, Madani TA. Isolated tuberculous orchitis presented as epididymo-orchitis: An unusual presentation of tuberculosis. *Urol Ann.* 2022;14: 189–195. [https://doi.org/10.4103/ua.ua\\_12\\_21](https://doi.org/10.4103/ua.ua_12_21)
27. Salem B. Disseminated tuberculosis following the placement of ureteral stents: a case report. *Cases J.* 2008;1. <https://doi.org/10.1186/1757-1626-1-383>
28. Nguyen HV, Tiemersma EW, Nguyen HB, Cobelens FGJ, Finlay A, Glaziou P, et al. The second national tuberculosis prevalence survey in Vietnam. *PLoS One.* 2020;15. <https://doi.org/10.1371/journal.pone.0232142>
29. Caulfield AJ, Wengenack NL. Diagnosis of active tuberculosis disease: From microscopy to molecular techniques. *J Clin Tuberc Other Mycobact Dis.* 2016;4: 33–43. <https://doi.org/10.1016/j.jctube.2016.05.005>
30. Hussein I, Kim Y, Modukuru V, Department of Internal Medicine, Metropolitan Hospital Center, New York Medical College, New York, New York, USA, Department of Internal Medicine, Metropolitan Hospital Center, New York Medical College, New York, New York, USA, Department of Internal Medicine, Metropolitan Hospital Center, New York Medical College, New York, New York, USA. Peritoneal Tuberculosis. *J Infect Dis Case Rep.* 2020; 1–3. [https://doi.org/10.47363/JIDSCR/2020\(1\)124](https://doi.org/10.47363/JIDSCR/2020(1)124)
31. Goletti D, Petruccioli E, Joosten SA, Ottenhoff THM. Tuberculosis Biomarkers: From Diagnosis to Protection. *Infect Dis Rep.* 2016;8. <https://doi.org/10.4081/idr.2016.6568>
32. Pandie S, Peter JG, Kerbelker ZS, Meldau R, Theron G, Govender U, et al. Diagnostic accuracy of quantitative PCR (Xpert MTB/RIF) for tuberculous pericarditis compared to adenosine deaminase and unstimulated interferon- $\gamma$  in a high burden setting: a prospective study. *BMC Med.* 2014;12. <https://doi.org/10.1186/1741-7015-12-101>
33. Yong YK, Tan HY, Saeidi A, Wong WF, Vignesh R, Velu V, et al. Immune Biomarkers for Diagnosis and Treatment Monitoring of Tuberculosis: Current Developments and Future Prospects. *Front Microbiol.* 2019;10. <https://doi.org/10.3389/fmicb.2019.02789>
34. Man J, Cao L, Dong Z, Tian J, Wang Z, Yang L. Diagnosis and treatment of epididymal tuberculosis: a review of 47 cases. *PeerJ.* 2020;8. <https://doi.org/10.7717/peerj.8291>
35. Khan FY, Hamza M, Omran AH, Saleh M, Lingawi M, Alnaqdy A, et al. Diagnostic value of pleural fluid interferon-gamma and adenosine deaminase in patients with pleural

- tuberculosis in Qatar. *Int J Gen Med*. 2013;6: 13–8. <https://doi.org/10.2147/IJGM.S39345>
36. Gupta M, Lobo FD, Adiga DSA, Gupta A.  
A Histomorphological Pattern Analysis of Pulmonary

Tuberculosis in Lung Autopsy and Surgically Resected Specimens. *Patholog Res Int*. 2016;2016. <https://doi.org/10.1155/2016/8132741>

# Diagnóstico tardío de tuberculosis diseminada: reporte de caso

## RESUMEN

**INTRODUCCIÓN** Los pulmones son más afectados en la tuberculosis. La infección también puede comprometer a otros órganos a través de la diseminación linfohematógena. La presentación del cuadro clínico de la tuberculosis diseminada es variable. El diagnóstico es difícil, porque las manifestaciones clínicas son diversas. Más del 50% de los pacientes acuden tardíamente, porque las pruebas microbiológicas dependen de procedimientos invasivos para el cultivo de micobacterias y la histopatología de apoyo.

**CASO CLÍNICO** Paciente varón de 30 años, persona privada de su libertad, sin comorbilidades, ingresó al hospital por dolor intenso en muñeca izquierda, con historia previa de haber recibido glucocorticoides sistémicos durante siete meses. Desarrolló cuadro clínico de tuberculosis pulmonar en pleura, en articulación de la muñeca izquierda y en testículo izquierdo. En los análisis se confirmó presencia de *Mycobacterium tuberculosis*. Fue intervenido quirúrgicamente en muñeca y en el testículo. Además, recibió tratamiento para tuberculosis sensible. Concomitantemente se diagnosticó secuelas de Cushing iatrogénico, anemia crónica y proctitis crónica inactiva.

**CONCLUSIONES** El diagnóstico de tuberculosis diseminada fue difícil debido al cuadro clínico inespecífico, a las limitaciones de herramientas de diagnóstico confirmatorio y a las evaluaciones especializadas en forma oportuna. El uso prolongado de corticoides sistémicos habría influido en la diseminación de la tuberculosis.



This work is licensed under a Creative Commons Attribution 4.0 International License.